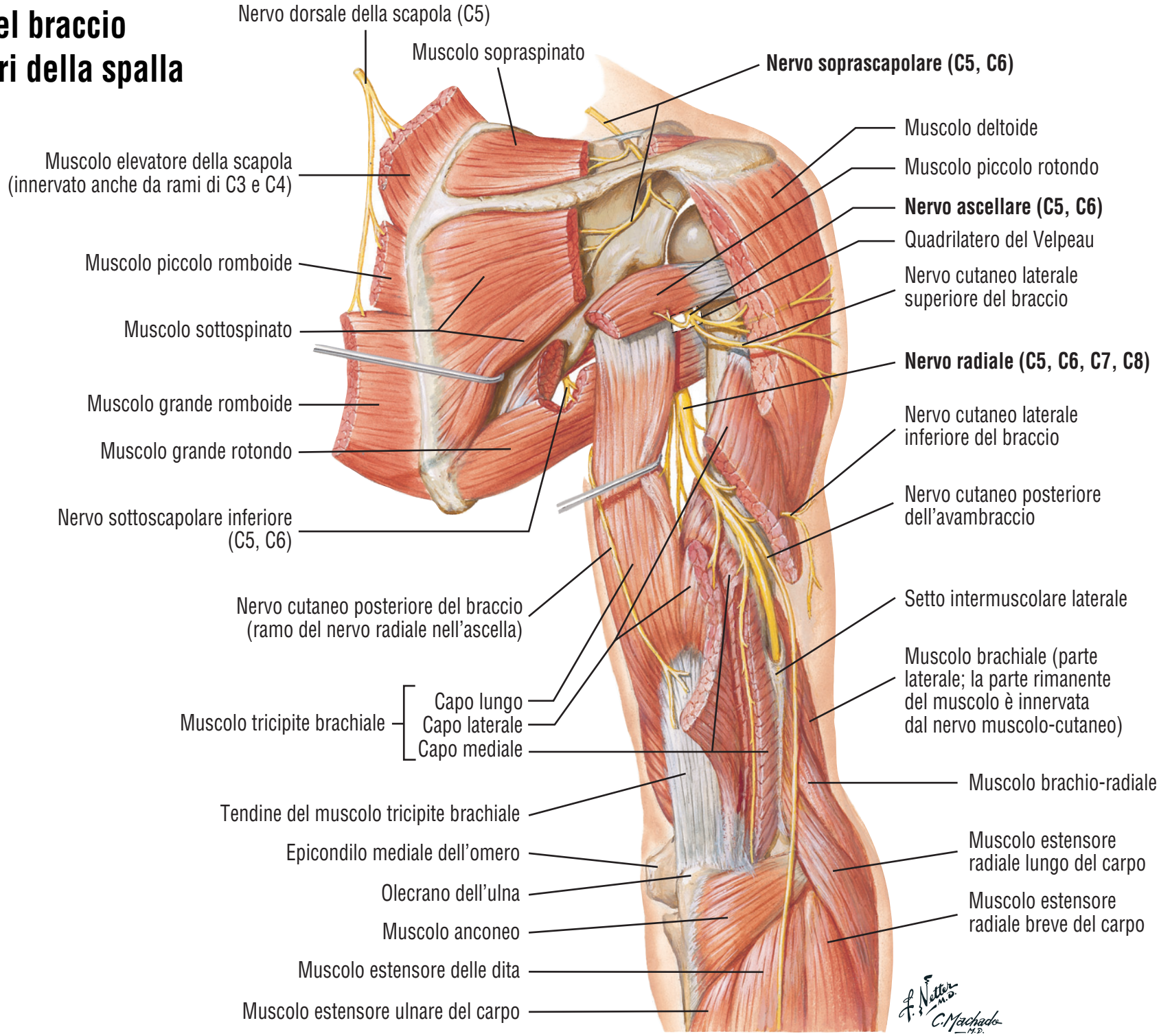Nervo radiale nel braccio e nervi posteriori della spalla