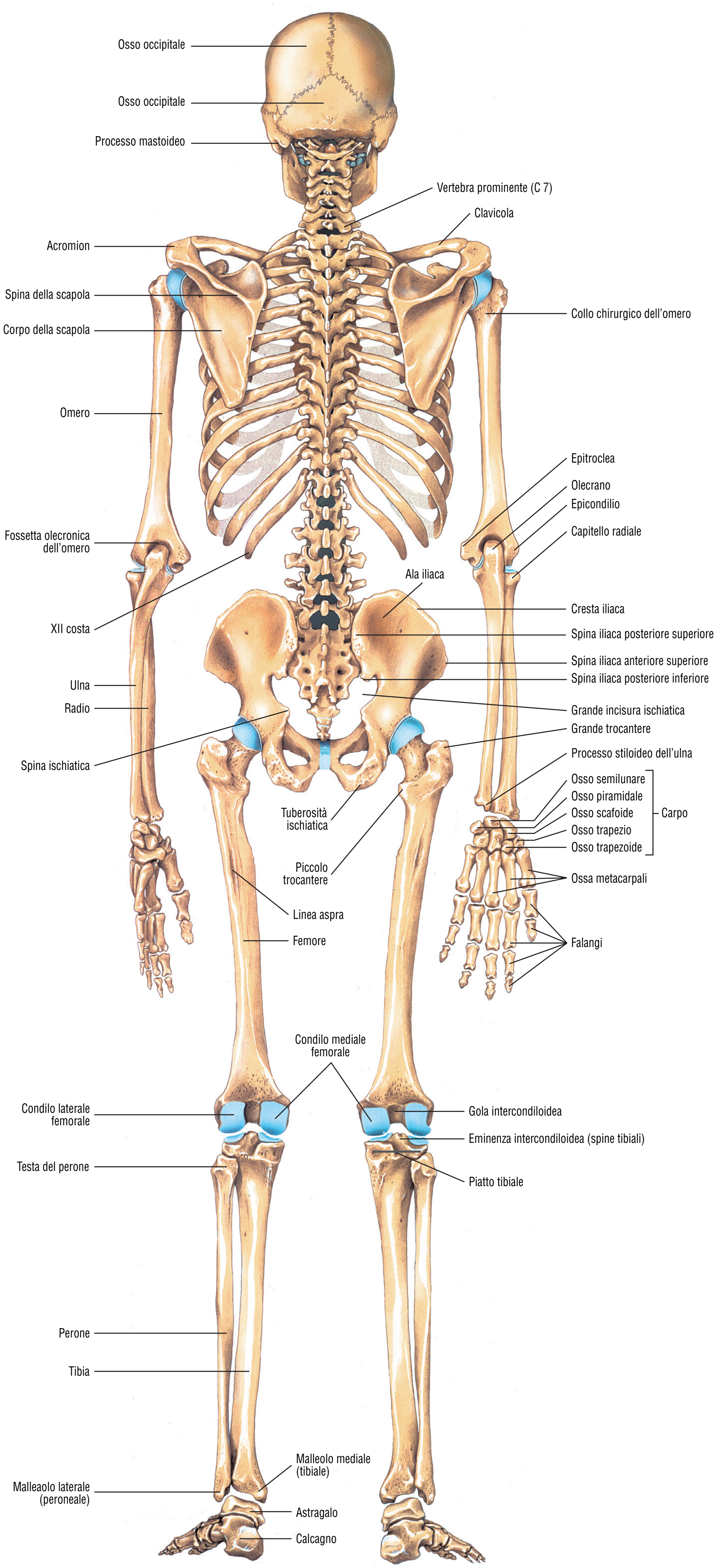Apparato scheletrico (visione posteriore)